



Update on new muscle glycogenosis

Pascal Laforêt^{a,b,c}, Edoardo Malfatti^{a,b,c}, and John Vissing^{a,b,c}

AQ1

AQ2

Purpose of review

The field of muscle glycogenoses has progressed in recent years by the identification of new disorders, and by reaching a better understanding of pathophysiology of the disorders and the physiology of glycogen metabolism.

Recent findings

In this review, we describe the clinical and pathological features of the three most recently described muscle glycogenoses caused by recessive mutations in *GYG1*, *RBCK1* and *PGM1*. The three involved enzymes play different roles in glycogen metabolism. Glycogenin-1 (GYG1) is involved in the initial steps of glycogen synthesis, whereas phosphoglucomutase catalyzes two metabolic pathways; the connection between galactose and glycogen on one side, and glucose metabolism on the other side. The metabolic consequences of mutations in the ubiquitin ligase gene *RBCK1* are still poorly understood. GYG1 deficiency has been associated with cardiomyopathies with abnormal storage material in the heart, but most cases present with a polyglucosan body myopathy without cardiac involvement.

Summary

The recent identification of new glycogenosis not only allows to improve the knowledge of glycogen metabolism, but also builds bridges with protein glycosylation and immune system.

Keywords

glycogenin-1, *GYG1*, metabolic myopathies, muscle glycogenosis, *PGM1*, phosphoglucomutase, polyglucosan body, *RBCK1*

INTRODUCTION

Muscle glycogenoses constitute a growing number of inborn errors of glycogen metabolism. Deficiencies of virtually all enzymes, which intervene in the synthesis or degradation of glycogen, may cause glycogen storage disease (GSD) because of aberrant storage or utilization of glycogen.

The different GSDs are each denoted by a roman numeral that reflects the historical sequence of their discovery and often also by the name of the author of the first description (Fig. 1). Muscle glycogenoses may be subclassified into the following categories: disorders of glycogen synthesis; disorders of glycogen breakdown; disorders of glycolysis; and lysosomal glycogenosis. The most frequent muscle glycogenoses are McArdle disease (GSDV), Pompe disease (GSDII) and debranching enzyme deficiency (GSDIII).

Clinical features are closely related to the enzyme deficiency, with either exercise intolerance associated with rhabdomyolysis episodes, or permanent muscle weakness. Other organs may also be involved such as heart or liver, depending on the involved enzyme and severity of enzyme deficiency.

In-vivo metabolic studies with exercise tests and muscle biopsy are important tools allowing precise diagnosis. Cycle and forearm exercise tests most often show blunted lactate increase during exercise. Vacuolar myopathy and increase glycogen content on PAS staining are the hallmarks on muscle biopsy. However, these characteristic features may lack in some glycogenoses.

We review here the clinical, pathological and molecular features of the three most recently described muscle glycogenoses due to mutations in

^aNord-Est-Ile de France Neuromuscular Reference Center, Groupe Hospitalier Pitié-Salpêtrière, Assistance Publique-Hôpitaux de Paris, ^bMyology Institute, Neuromuscular Pathology Reference Center, Groupe Hospitalier Universitaire La Pitié-Salpêtrière, Sorbonne Universités UPMC Univ Paris 06, Paris, France and ^cCopenhagen Neuromuscular Center, Department of Neurology, Rigshospitalet, University of Copenhagen, Copenhagen, Denmark

Correspondence to Dr Pascal Laforêt, Centre de Référence de pathologie neuromusculaire Paris-Est, Groupe Hospitalier Pitié-Salpêtrière, Assistance Publique-Hôpitaux de Paris, 75651 Paris, France. Tel: +33142163776; fax: + 33142163793; e-mail: pascal.laforet@psl.aphp.fr

Curr Opin Neurol 2017, 30:000–000

DOI:10.1097/WCO.0000000000000484

Nerve, neuro-muscular junction and motor neuron diseases

KEY POINTS

- The field of muscle glycogenesis has been extended in the recent years with description of new glycogenesis.
- Polyglucosan body inclusions in muscle biopsies are major hallmarks of *GYG1* deficiency and *RBCK1* gene mutations.
- Glycogen accumulation is generally not observed in PGM1 deficiency, but abnormal transferrin glycosylation pattern may be observed after transferrin isoelectric focusing.
- Several symptoms observed in PGM1 deficiency could be improved with galactose supplementation.

GYG1, *PGM1* and *RBCK1* genes, with emphasis on the muscle biopsy analysis to continue to decipher the field of muscle glycogenoses.

PHOSPHOGLUCOMUTASE TYPE 1 DEFICIENCY

Phosphoglucomutase type 1 (PGM1) deficiency is novel inborn error of glycosylation, identified in 2009 [1].

PGM1 acts as a key enzyme between glycolysis and glycogenesis, catalyzing the interconversion of glucose-1-phosphate and glucose-6-phosphate, operating a bidirectional transfer of phosphate from position 1 to 6 on glucose. PGM has an important role in several metabolic pathways: in the maintenance of normoglycemia during fasting; in the regulation of glycogen synthesis and in the regulation of concentration of activated monosaccharides essential for protein glycosylation. This enzyme is thus involved not only in glycogen metabolism, but also in protein glycosylation process, leading to two major phenotypes; one with predominant muscle involvement, and the other with multisystem disease. The main biochemical characteristic of this enzyme deficiency is a decreased transferrin glycosylation, with a mixed type 1 and type 2 pattern of serum transferrin isoelectric focusing.

The first pathogenic mutations in the *PGM1* gene coding for the muscle-specific PGM1 isoform, and resulting in phosphoglucomutase deficiency in muscle, were found in a patient with primary muscle involvement, characterized by episodes of exercise-induced rhabdomyolysis mimicking McArdle disease [1]. Only two patients with muscle symptoms and PGM deficiency had previously been reported in the literature, but they were not genetically

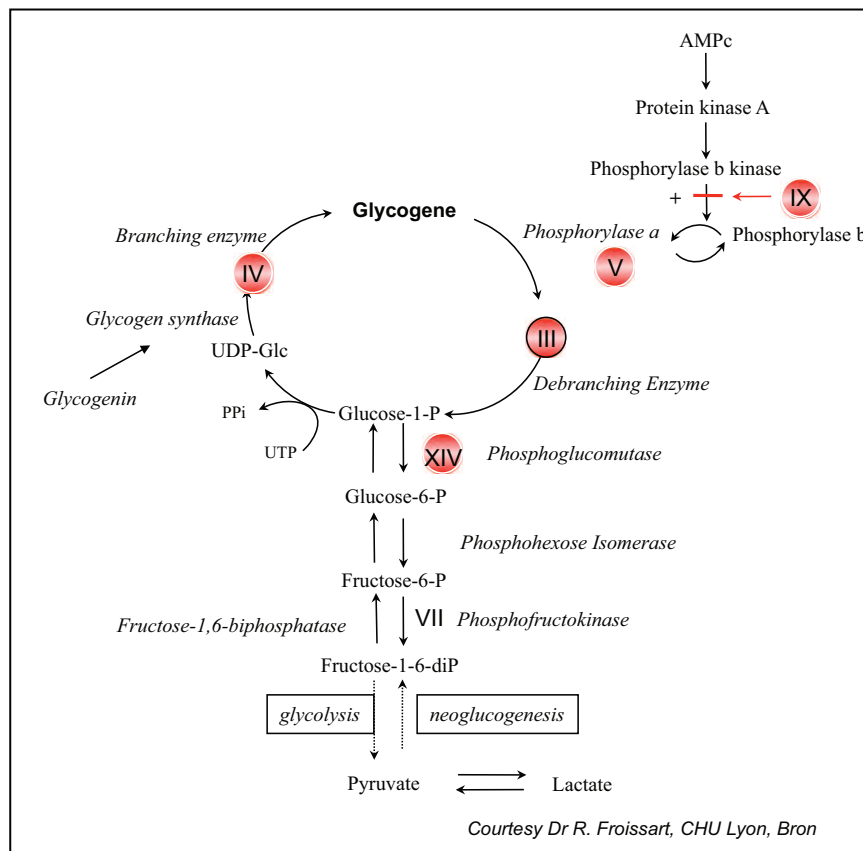


FIGURE 1. Glycogenolytic and glycolytic pathways showing the main enzymes involved in muscle glycogenoses.

confirmed [2,3]. A recently reported case, diagnosed at the age of 52 years after an episode of rhabdomyolysis, also presented with growth retardation and dilated cardiomyopathy, suggesting an overlap between the myopathic and multisystem phenotypes [4]. An abnormal protein glycosylation profile characteristic for PGM1-CDG was detected in the plasma of this patient.

Mutations in the same gene have been discovered soon after the description of this new metabolic myopathy, by whole-exome sequencing in patients with multisystemic disorder classified as having congenital disorder of glycosylation [5]. So far, more than 20 different PGM1 mutations have been identified [5,6]. The spectrum of symptoms that may be observed are malformations (cleft palate, uvula bifida or Pierre–Robin sequence), endocrine symptoms (hypogonadism, adrenal insufficiency and growth retardation), elevated serum transaminases, hypoglycemia, coagulation abnormalities and dilated cardiomyopathy. In addition, some of these patients, mostly children, may show muscle symptoms such as malignant hyperthermia and episodes of rhabdomyolysis. A considerable variability of the clinical phenotype and severity of the disease has been highlighted recently, with the report of the clinical picture of seven affected patients from a consanguineous family [7]. However, characteristics and natural history of the muscle symptoms that may be observed in children with multisystemic disorder are still unknown. Mass spectrometry of transferrin shows similar profiles in all patients, with transferrin glycoforms lacking one or both glycans, as well as forms with truncated glycans lacking galactose. The abnormal glycoproteins in PGM1 deficiency are most likely due to the decreased availability of UDP-Galactose compared to UDP-Glucose for the proper glycosylation [6].

In contrast to patients with McArdle disease, in whom lactate production is blocked [7,8], the patient reported by Stojkovic *et al.* [1] had a normal lactate response to forearm exercise, but abnormally high ammonia levels. The forearm exercise test may thus provide an important biological clue for the diagnosis of PGM deficiency when showing an exaggeration of ammonia levels, even without blunted increase in lactate level. Considering muscle biopsy analysis, neither vacuoles nor significant increase in glycogen content on PAS staining has been observed on muscle biopsies described by Stojkovic *et al.* [1] and Voermans *et al.* [4]. These results show that disorders of muscle glycogen metabolism may be easily missed on muscle biopsy analysis from patients with PGM1 deficiency, as it has also been observed in some rare disorders of glycolysis.

Exercise studies in PGM1 deficiency have shown that fat oxidation during exercise tends to be

increased to compensate for the partial block in carbohydrate breakdown [4,9]. As the enzymatic defect is proximal to the entry of glucose into glycolysis, it could be hypothesized that a second wind phenomenon could also occur in PGM1 deficiency. However, this was not the case in the two first patients who were studied during exercise [4,9], but a third more severely affected patient with lower residual PGM1 activity in muscle did show a second wind phenomenon identical to that seen in McArdle disease (unpublished observations). So far, the second wind phenomenon was considered pathognomonic for McArdle disease, but now PGM1 should also be considered with this symptom.

In-vitro studies in patient fibroblasts show an improved glycosylation after galactose supplementation. Initial results from an open trial of D-galactose supplementation in young patients suggested improvement of growth and liver function, and a decrease in frequency of hypoglycemic episodes [6]. Protein glycosylation profile was also improved in these patients. Voermans *et al.* also reported the effect of oral galactose treatment in an adult with PGM1 deficiency with predominant muscle symptoms. After 5 months of treatment with galactose, there was an improvement of walking distance, a normalization of muscle substrate use during exercise and restoration of near-normal levels of transferrin glycosylation. However, neither peak exercise tolerance, nor muscle strength improved after galactose supplementation. Therefore, based on available clinical data, treatment with D-galactose should be considered in patients with PGM1 deficiency [10].

PGM1 deficiency should thus be considered in patients with exercise intolerance early in exercise and episodes of rhabdomyolysis, even with a normal lactate production during exercise and without overt increase of glycogen content on muscle biopsy. Transferrin isoelectric focusing should be performed and may show a mixed CDGI/II profile.

GLYCOGENIN 1 DEFICIENCY: A TALE OF TWO DISEASES

Glycogenin activates the first step of glycogen synthesis. It is an autoglycosylated glycosyltransferase that catalyzes the formation of a short glucose polymer of approximately 10 glucose residues. There are two glycogenin isoforms: glycogenin-1 (GYG1), encoded by *GYG1*, is the muscle isoform, but is also expressed in other tissues to a lesser degree; glycogenin-2, encoded by *GYG2*, is the liver isoform, which besides the liver is also expressed in cardiac, but not in skeletal muscle.

Recessively, mutations of *GYG1*, leading to inactivation of autoglycosylation of *GYG1*, were first

Nerve, neuro-muscular junction and motor neuron diseases

reported in a 27-year-old man with exercise intolerance, muscle weakness and cardiac arrhythmia associated with hypertrophic cardiomyopathy [11]. This patient experienced dizziness and palpitations shortly after exercising, complicated by an episode of ventricular fibrillation leading to cardiac defibrillation and placement of an implantable cardioverter-defibrillator. Interestingly, muscle biopsy morphologic and histochemical analyses were similar to GSD0 [12], thus showing profound glycogen depletion, a marked predominance of type 1 oxidative muscle fibers and mitochondrial proliferation. In contrast, large vacuoles of PAS-positive material were detected in the myocardial biopsy. Western blot analysis of GYG1 in muscle showed exclusively unglycosylated, defective, GYG1. Only a handful of patients with this cardiac phenotype have been described all presenting with cardiac failure often necessitating cardiac transplantation [13].

A few years after the identification of the first case of GYG1 deficiency, a series of seven patients with other *GYG1* mutations and a different phenotype were reported [14]. All these patients presented at adult age with a slowly progressive myopathy without cardiac involvement. Four patients developed proximo-distal muscle weakness with variable involvement of hip and shoulder girdle muscles, and calf and hand muscles. Two patients showed isolated proximal muscle weakness. One patient showed only hand and finger involvement starting in adulthood. Serum creatine kinase was normal in all patients, but one. Electrocardiography and cardiac ultrasound were normal in all patients.

In sharp contrast with the depletion of glycogen observed in the biopsy of the first reported patient with GYG1 deficiency, a PAS-positive storage material was found in around 30–40% of muscle fibers of the patients [14]. α -Amylase treatment showed a variable degree of digestion of the PAS-positive material, thus sharing similarities with polyglucosan body myopathies of other causes, such as branching and phosphofructokinase enzyme deficiencies and these forms have been classified in OMIM as polyglucosan body myopathy 2 (OMIM # 616199. POLYGLUCOSAN BODY MYOPATHY 2; PGBM2). Genetic investigation revealed homozygous or compound heterozygous deleterious variants in *GYG1*. The most frequent variant was c.143+3G>C, identified in four patients from different ethnic backgrounds. This common splice site variant caused alternative splicing, exon 2 skipping and profound reduction of wild-type GYG1.

To date, less than 30 patients with late-onset polyglucosan body myopathy and proximal weakness due to *GYG1* mutations have been reported [14,15–19], suggesting that mutations associated

with glycogen depletion and heart involvement are much rarer than those associated with polyglucosan body myopathy and no heart involvement. It appears that disease progression and pattern of muscle involvement can be quite variable and even asymmetric in the myopathic form of GYG1 deficiency.

Interestingly, cardiac and respiratory muscles are spared in all patients reported with the myopathic form so far, and the same intronic c.143+3G>C mutation was detected in homozygous state in most patients, except in Chinese patients in whom genetic analysis revealed a homozygous novel mutation in exon 6 of the *GYG1* gene (c.634C>T, p.His212Tyr) [17].

It is an enigma, not only that the disease is associated with two distinct phenotypes, but also that patients are able to produce muscle glycogen at all, considering that mutations generally result in severely reduced, nonfunctional protein, and yet normal looking glycogen granules, albeit somewhat larger than normal, are present on electron microscopy. Glycogen levels have been demonstrated to be within normal limits [20]. The polyglucosan bodies have often been shown to have a lobulated grape structure composed of oval subunits and consist of a mixture of dense filamentous material, normal or altered glycogen deposits and myofibrillar proteins of various sorts. Glycogenin 2, which is absent in health muscle, is highly expressed in patients with GYG1 deficiency, which may explain the rescue of glycogen formation. GYG1 and 2 can heterodimerize. As cardiac muscle consists of type I fibers, and unlike skeletal muscle expresses glycogenin 2, it is possible that the functional glycogenin 2 heterodimerizes with nonfunctional GYG1, which then by a dominant-negative effect renders the dimer nonfunctional as shown *in vitro* [21]. This may then also explain the great discrepancy in phenotype between primary cardiac vs. myopathic forms of the disease.

Some GYG1 patients report exercise intolerance. The glycogenosis is generally viewed as a GSD with fixed weakness and not dynamic, exercise-related symptoms. It follows that exercise intolerance merely could be the result of this weakness, which comes about from the affected myofibril ultrastructure in type II fibers due to the intermyofibrillar glycogen accumulation in patients. However, it has recently been shown that GYG1 deficiency also has an exercise-induced dynamic, energy deficiency component to its phenotype. GYG1 deficiency, besides the defect in glycogen synthesis imposed by the GYG1 defect, also has impaired breakdown of muscle glycogen during exercise. Thus, during exercise, patients with GYG1 deficiency produce half the amount of lactate despite a higher neurohormonal signal for glycogenolysis [22]. In keeping with this, intravenously

supplied glucose improves exercise tolerance in the patients [22]. The breakdown of glycogen is likely impaired in GYG1 deficiency, because the target for glycogenolytic enzymes is altered and inaccessible due to mislocalization and pooling of glycogen to the intermyofibrillar space.

MUSCLE AND CARDIAC GLYCOGENOSIS DUE TO *RBCK1* GENE MUTATIONS

Loss-of-function mutations in *RBCK1* (*HOIL-1*) gene, coding for the E3 ubiquitin ligase, were initially found in three young children with failure to thrive, chronic autoinflammation and recurrent episodes of sepsis [23]. Two of the children died from sepsis at ages 8 and 3.5 years; and one child, who had an allogeneic bone marrow transplantation at 13 months of age, died from sudden respiratory distress at 4 years of age. Accumulation of polyglucosan was identified in skeletal muscle, heart and liver at autopsy.

Mutations in the same gene were also identified in 10 patients from eight families with childhood or juvenile onset of myopathy, eight of whom also had rapidly progressive cardiomyopathy, requiring heart transplant in four [24]. Extensive polyglucosan accumulation was detected in skeletal muscle and in the heart in cases of cardiomyopathy. For this reason, this condition has been classified in OMIM as polyglucosan body myopathy 1 (OMIM # 615895. POLYGLUCOSAN BODY MYOPATHY 1; PGBM1). All these patients were homozygous or compound heterozygous for missense or truncating mutations in *RBCK1* gene, and none of them had recurrent episodes of sepsis or apparent chronic autoinflammation. Prognosis of this new disorder is poor because of the severity of the cardiomyopathy.

MUSCLE MORPHOLOGICAL FINDINGS

RBCK1 and GYG1 deficiency

Muscle tissue has PAS-positive inclusions corresponding to polyglucosan bodies in both *RBCK1*-PGBM1 and *GYG1*-PGBM2. Inclusions may affect different proportions of muscle fibers. These distinctive features render histopathology fundamental in the diagnostic workup and detailed histological, immunohistochemical and ultrastructural analyses help distinguishing among *RBCK1*-PGBM1 and *GYG1*-PGBM2.

On H&E, PGBM1 cases show the presence of basophilic dotted inclusions widespread in the cytoplasm; less frequently inclusions are found as thicker subsarcolemmal crescent or, exceptionally as centrally round structures (Fig. 2a). In contrast, PGBM2 muscles harbor bigger round or oval subsarcolemmal or cytoplasmic inclusions that appear pinkish matt

and uneven, sometimes including myonuclei (Fig. 2b). PAS staining confirms the above described pattern of lesions. The majority of fibers with inclusions show marked glycogen depletion (Fig. 2c and d) and there is a striking difference in α -amylase resistance consisting of major resistance of dotted inclusion in *RBCK1*-PGBM1, whereas only bigger inclusions showed resistance in *GYG1*-PGBM2 (Fig. 2e and f).

Immunohistochemical studies confirmed the deposition of numerous myofibrillar and ubiquitin proteasome system proteins inside the inclusions. However, we noticed that tiny dotted inclusions, peculiar of *RBCK1*-PGBM1, are particularly immunoreactive for P62 compared to desmin (Fig. 2g and h). This finding could explain the increased α -amylase resistance of the small inclusion described above.

With ultrastructural studies, full-blown polyglucosan bodies are found both in subsarcolemmal and cytoplasmic areas. They are nonmembrane bound and span up to 30–40 sarcomeres (Fig. 3a). The lobulated grape structure is always present and each acinus is separated by a thin rim of normally structured and electron dense glycogen granules in *GYG1*-PGBM2, and mainly mitochondria in *RBCK1*-PGBM1. At higher magnification, they show to be invariantly composed of partly filamentous material intermingled with glycogen granules (Fig. 3b). In *RBCK1*-PGBM1, and to lesser extent in PGBM2, smaller deposits of normal glycogen with some partly filamentous material initially dissociating normally structured myofibrils (Fig. 3c) are also visible. These structures appear to progressively dissociate myofibrils and successively disrupt the sarcomeric structure (Fig. 3d). We frequently observed remnants of sarcomere inside the polyglucosan bodies suggesting the dissolution of myofibrils (Fig. 3d).

As a whole, *RBCK1* and *GYG1* PGBMs have different morphological features. A fine histopathological analysis allows to discriminate the two conditions and suggests the genetic diagnosis. The pathological mechanism of polyglucosan body formation remains unknown. On the basis of IHC studies, one may suggest that protein deposition could be the seminal mechanism in *RBCK1*-PGBM1. Ongoing studies of molecular dissection of polyglucosan bodies may help disclosing disease mechanism and potential therapeutic avenues.

PHOSPHOGLUCOMUTASE TYPE 1 DEFICIENCY

In sharp contrast with the characteristic muscle findings in *RBCK1* and *GYG1*, muscle findings in phosphoglucomutase are generally unspecific and not very helpful in the diagnostic algorithm. Muscle biopsy in a previously reported patient failed to

AQS

Nerve, neuro-muscular junction and motor neuron diseases

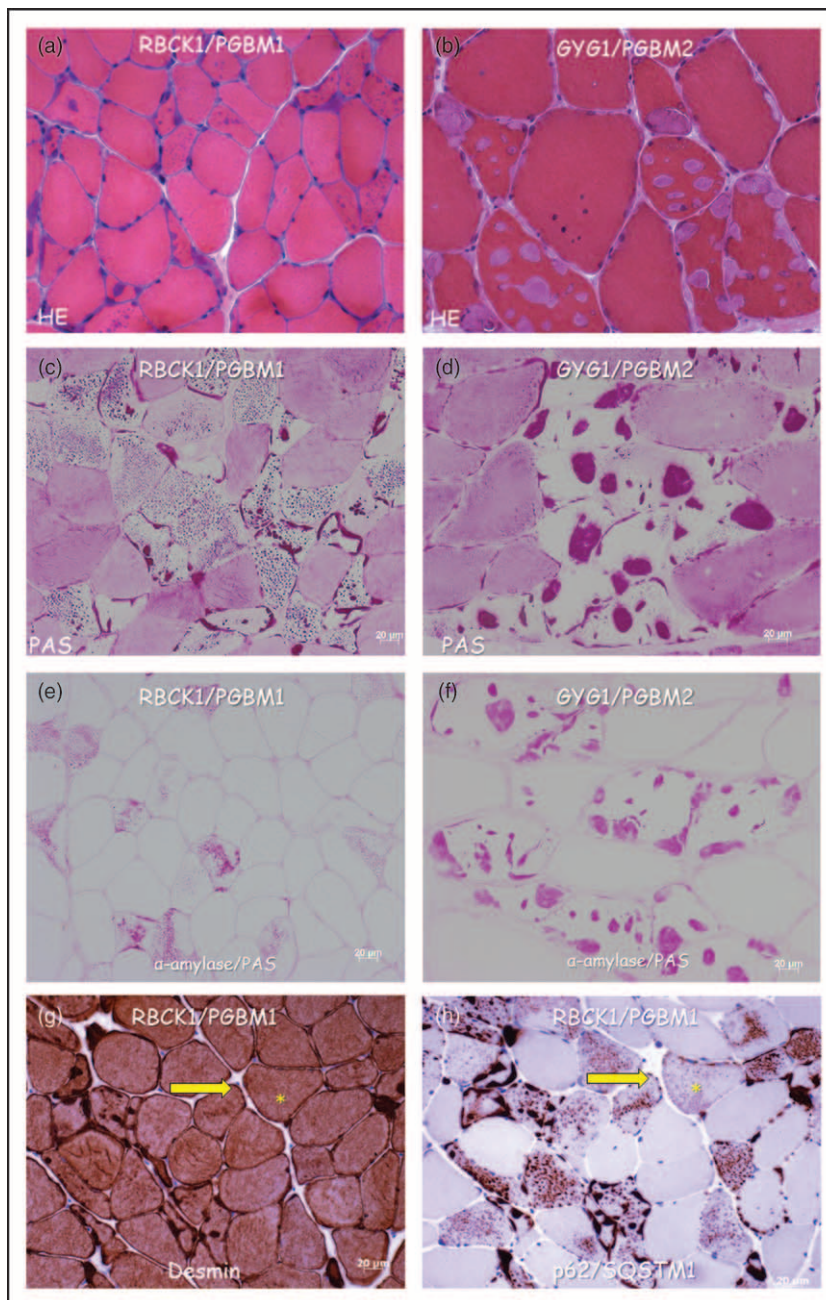


FIGURE 2. Histological and immunohistochemical muscle biopsy features in patients with *RBCK1-PGBM1* and *GYG1-PGBM2*. (a) *PGBM1*, H&E. Basophilic dotty inclusions are found widespread inside the cytoplasm of often atrophic muscle fibers. Thicker subsarcolemmal crescent shaped and centrally round inclusions are also seen. (b) *PGBM2*, H&E. Round or oval subsarcolemmal and cytoplasmic inclusions that appear pinkish matt and contain darker and rounded subunits. Myonuclei are sometimes observed inside or in vicinity of the inclusions. (c) *PGBM1*, PAS. Presence of the same and easy recognizable lesion pattern. Marked glycogen depletion in areas surrounding the inclusions. (d) *PGBM2*, PAS. Presence of the same and easy recognizable lesional pattern. Marked glycogen depletion in areas surrounding the inclusions. (e) *PGBM1*, PAS/ α -amylase. Dotty cytoplasmic inclusions appear more resistant to digestion compared to subsarcolemmal, thicker inclusions. (f) *PGBM2*, PAS/ α -amylase. Bigger dotty inclusions show higher resistance to digestion. (g) (h). Serial cross-section underwent desmin and p62 immunohistochemistry. Notice the P62 immunoreactivity of small dotty lesion that cannot be appreciated with desmin of the same fiber (indicated by an arrow and the asterisk).




FIGURE 3. Electron micrographs from *RBCK1-PGBM1* and *GYG1-PGBM2* muscle samples. (a) PGBM1. Multiple grape structure polyglucosan bodies of different sizes are visible in both cytoplasmic and subsarcolemmal regions. (b) PGBM1. Each acinus is separated by mitochondria and glycogen granules and is made of partly filamentous and denser protein. (c) PGBM1. Small deposits of normal glycogen with some partly filamentous material dissociating normally structured myofibrils (indicated by arrows). Proliferation and progressive disruption of the sarcomeric structure (indicated by an asterisk). Full-blown polyglucosan body is present in the left part of the picture. (d) PGBM2. Remnants of a sarcomere dispersed inside the polyglucosan body.

show increase in glycogen content. No other specific histopathological lesions were appreciated.

CONCLUSION

The field of glycogenoses has been widely expanded during the past years with the discovery of new metabolic disorders, allowing at the same time to decipher new metabolic pathways such as phosphoglucomutase that bridges GSD and congenital glycosylation disorders. Several important pathophysiological issues remain unsolved such as the mechanisms of polyglucosan bodies formation related to *RBCK1* and *GYG1* gene mutations. Treatment approaches also need to be developed, but preliminary in-vitro and clinical data suggest that galactose supplementation could benefit for patients with PGM1 deficiency [14,15].

Acknowledgements

We acknowledge Jean-Yves Hogrel (Myology Institute, Neuromuscular Pathology Unit, Pitié-Salpêtrière Hospital) for providing results of grip test.

Financial support and sponsorship

None.

Conflicts of interest

There are no conflicts of interest.

REFERENCES AND RECOMMENDED READING

Papers of particular interest, published within the annual period of review, have been highlighted as:

- of special interest
- of outstanding interest

1. Stojkovic T, Vissing J, Petit F, *et al.* Muscle glycogenosis due to phosphoglucomutase 1 deficiency. *N Engl J Med* 2009; 3614:425–427.
2. Sugie H, Kobayashi J, Sugie Y, *et al.* Infantile glycogen storage disease: phosphoglucomutase deficiency with decreased muscle and. [AQ6](#)
3. Thomson WHS, Maclaurin JC, Prineas JW. Skeletal muscle glycogenosis: an investigation of two similar cases. *J Neurol Neurosurg Psychiatry* 1963; 26:60–68.
4. Voermans NC, Preisler N, Madsen KL, *et al.* PGM1 deficiency: substrate use during exercise and effect of treatment with galactose. *Neuromuscul Disord* 2017; 27:370–376.
5. Tegtmeyer LC, Rust S, van Scherpenzeel M, *et al.* Multiple phenotypes in phosphoglucomutase 1 deficiency. *N Engl J Med* 2014; 3706: 533–542.
6. Morava E. Galactose supplementation in phosphoglucomutase-1 deficiency; review and outlook for a novel treatable CDG *Mol Genet Metab* 2014; [AQ7](#) 112:275–279.

Nerve, neuro-muscular junction and motor neuron diseases

7. Loewenthal N, Haim A, Parvari R, Hershkovitz E. Phosphoglucomutase-1 deficiency: intrafamilial clinical variability and common secondary adrenal insufficiency. *Am J Med Genet A* 2015; 167A:3139–3143.
 8. Hogrel JY, van den Bogaart F, Ledoux I, *et al.* Diagnostic power of the nonischaemic forearm exercise test in detecting glycogenosis type V. *Eur J Neurol* 2015; 22:933–940.
 9. Preisler N, Laforêt P, Echaniz-Laguna A, *et al.* Fat and carbohydrate metabolism during exercise in phosphoglucomutase type 1 deficiency. *J Clin Endocrinol Metab* 2013; 98:E1235–1240.
 10. Schrapers E, Tegtmeier LC, Simic-Schleicher G, *et al.* News on clinical details and treatment in PGM1-CDG. *JIMD Rep* 2016; 26:77–84.
 11. Moslemi A-R, Lindberg C, Nilsson J, *et al.* Glycogenin-1 deficiency and inactivated priming of glycogen synthesis. *N Engl J Med* 2010; 362:1203–1210.
 12. Kollberg G, Tulinius M, Gilljam T, *et al.* Cardiomyopathy and exercise intolerance in muscle glycogen storage disease. *N Engl J Med* 2007; 357:1507–1514.
 13. Hedberg-Oldfors C, Glamuzina E, Ruygrok P, *et al.* Cardiomyopathy as presenting sign of glycogenin-1 deficiency-report of three cases and review of the literature. *J Inherit Metab Dis* 2016; 40:139–141.
 14. Malfatti E, Nilsson J, Hedberg-Oldfors C, *et al.* A new muscle glycogen storage disease associated with glycogenin-1 deficiency. *Ann Neurol* 2014; 76:891–898.
 15. Fanin M, Torella A, Savarese M, *et al.* GYG1 gene mutations in a family with polyglucosan body myopathy. *Neurol Genet* 2015; 1: AQ8
 16. Colombo I, Pagliarani S, Testolin S, *et al.* Longitudinal follow-up and muscle MRI pattern of two siblings with polyglucosan body myopathy due to glycogenin-1 mutation. *J Neurol Neurosurg Psychiatry* 2016; 87:797–800.
 17. Luo S, Zhu W, Yue D, *et al.* Muscle pathology and whole-body MRI in a polyglucosan myopathy associated with a novel glycogenin-1 mutation. *Neuromuscul Disord* 2015; 25:780–785.
 18. Akman HO, *et al.* Late-onset polyglucosan body myopathy in five patients with a homozygous mutation in GYG1. *Neuromuscul Disord* 2016; 26: AQ9
 19. Tasca G, Fattori F, Monforte M, *et al.* Start codon mutation of GYG1 causing late-onset polyglucosan body myopathy with nemaline rods. *J Neurol* 2016; 263:2133–2135.
 20. Krag T, Ruiz CR, Vissing J. Glycogen synthesis in glycogenin 1 deficient patients; a role for glycogenin 2 in muscle. *J Clin Endo Metab* 2017; doi: 10.1210/jc.2017-00399. [Epub ahead of print] AQ10
- This article provides a possible explanation to the enigma of how glycogen formation is possible when the essential building block, GYG1, is missing in GYG1 deficiency. The suggestion is that the glycogenin 2 isoform, not normally expressed in skeletal muscle, can partially rescue glycogen formation.
21. Nilsson J, Halim A, Larsson E, *et al.* LC-MS/MS characterization of combined glycogenin-1 and glycogenin-2 enzymatic activities reveals their self-glucosylation preferences. *Biochim Biophys Acta* 2014; 1844:398–405.
 22. Stemmerik M, Laforêt P, Buch AE, Madsen KL, Vissing J. Sugar infusion improves exercise capacity in patients with glycogenin-1 deficiency. Abstract Book for the 14th International Congress on Neuromuscular Diseases, Toronto, Canada, 2016, p S179 (Abstract #195) 2016.
 23. Boisson B, Laplantine E, Prando C, *et al.* *Nat Immunol* 2012; 13: 1178–1186. AQ11
 24. Nilsson J, Schoser B, Laforet P, *et al.* Polyglucosan body myopathy caused by defective ubiquitin ligase RBCK1. *Ann Neurol* 2013; 74:914–919.

WCO

Manuscript No. 300516

Current Opinion in Neurology
Typeset by Thomson Digital
for Wolters Kluwer

Dear Author,

During the preparation of your manuscript for typesetting, some queries have arisen. These are listed below. Please check your typeset proof carefully and mark any corrections in the margin as neatly as possible or compile them as a separate list. This form should then be returned with your marked proof/list of corrections to the Production Editor.

QUERIES: to be answered by AUTHOR/EDITOR?

QUERY NO.	QUERY DETAILS	RESPONSE
<AQ1>	Please check whether affiliation links have been correctly identified in author byline.	
<AQ2>	Please confirm whether surnames/family names (red) have been identified correctly in the author byline.	
<AQ3>	Please check affiliation and correspondence for correctness.	
<AQ4>	Please provide the full form of PAS, CDG, UDP, IHC.	
<AQ5>	Please check whether the intended meaning of the sentence "Muscle biopsy . . . increase in glycogen content" remains the same after making the edits.	
<AQ6>	Please provide correct article title, journal title, volume number, page range and year of publication in 2.	
<AQ7>	As the following references are outside the review period, bullets and annotations have been deleted as per style. Refs. [6,9,11,14,23,24].	
<AQ8>	Please provide page range in 15,18.	
<AQ9>	As per style, a minimum of 3 author names must be listed before et al., unless there are only 4 authors, in which case all need to be listed. Please provide missing author names in the following reference.	
<AQ10>	Please provide volume number and page range in 20.	
<AQ11>	Please provide article title in 23.	